

# Biliary Papillomatosis - A Rare Cause of Recurrent Cholangitis and Biliary Obstruction

Kam Juinn Huar<sup>FE</sup>, Chan Chung Yip<sup>F</sup>, Khor Jen Lock Christopher<sup>G</sup> and Tan Meng Yew Damien<sup>G</sup>

<sup>1</sup>Department of Hepatopancreatobiliary and Transplant Surgery, Singapore General Hospital, Level 5 Academia, 20 College Road, Singapore


<sup>2</sup>Department of Gastroenterology and Hepatology, Singapore General Hospital, Level 5 Academia, 20 College Road, Singapore

<sup>F</sup>Corresponding author: [kamjuinn.huar@sgh.com.sg](mailto:kamjuinn.huar@sgh.com.sg)

Rec date: Acc date: Pub date:

Copyright: All rights reserved. No part of this publication may be reproduced, stored in a retrieval system, or transmitted, in any form or by any means, electronic, mechanical, photocopying, recording, or by any information storage or retrieval system, without the prior written permission of the publisher.

Biliary papillomatosis is a rare bile duct pathology with papillary adenomatous growth of varying extent involving intra and extrahepatic biliary system. It may present with obstructive jaundice or cholangitis. Biliary imaging may show multiple filling defects. This may be mistaken as multiple biliary stones which often present concomitantly. Biliary papillomatosis is a premalignant condition and surgical resection provides the best form of curative treatment for suitable patients. In our patient, the preoperative histological diagnosis of high grade dysplasia was obtained from ERCP. The papillomatous growth has involved left hepatic duct proximally and distally into ampulla of Vater as shown in MRCP and endoscopy. The patient underwent left hepatectomy and pylorus preserving pancreaticoduodenectomy successfully (Figures 1-4).



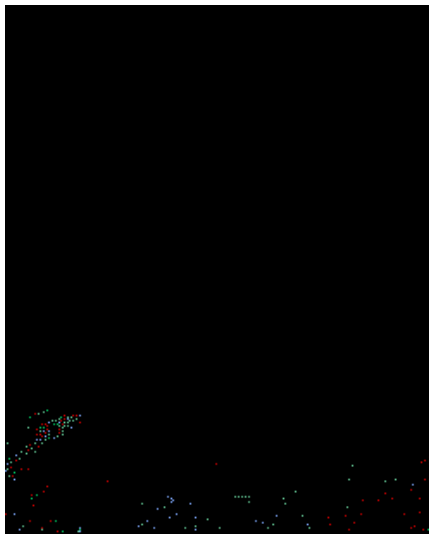


Figure 4