

COVID-19 Associated Pulmonary Fungal Ball and Arterial Thrombosis: A Rare Two Case Report

Gulden Unlu*

Department of Operative Dentistry and Endodontics, Dicle University, Diyarbakir, Turkey

Corresponding author: Gulden Unlu, Department of Operative Dentistry and Endodontics, Dicle University, Diyarbakir, Turkey, Tel: 05323593276; E-mail: cicekgulden@yahoo.com

Received: 03-Aug-2022; Manuscript No: JIDT-22-71164; **Editor assigned:** 08-Aug-2022; PreQC No: JIDT-22-71164 (PQ); **Reviewed:** 22-Aug-2022; QC No: JIDT-22-71164; **Revised:** 13-Dec-2022; Manuscript No: JIDT-22-71164 (R); **Published:** 10-Jan-2023; DOI: 10.4172ed:

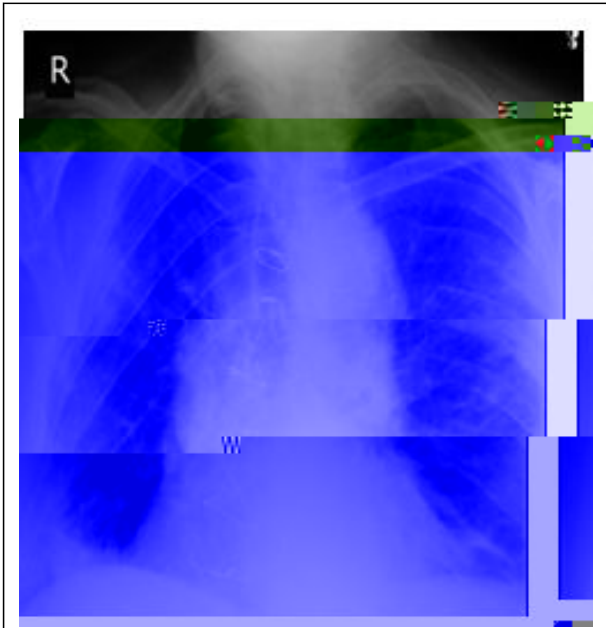


Figure 2: Chest X-Ray view. Consolidations and patch lesions.

Nasopharyngeal swab polymerase chain reaction for COVID-19 tested positive. RT-PCR test was evaluated by the Turkish ministry of health, department of microbiology reference laboratory of using BIO RAD, CFX real-time PCR system, (ABD). COVID-19 RT-PCR kit, Bioeksen (Turkey). Blood and respiratory cultures were drawn. Due to progressive respiratory distress, the patient was initially placed on high-flow nasal cannula [3]. He started on faviprevar, prednisolon based on current COVID-19 recommendations. With persistent fever spikes to 38°C, he was initiated on broad-spectrum antibioticsM CFX

