

# Diabetic Keto Acidosis and Hyperosmolar Hyperglycemic State, Diagnosis and Management Challenges at Regional Referral Hospitals, A Case Series from Tumbi Regional Referral Hospital, Pwani, Tanzania

Adam M Gembe\* and Bilaro E

Internal Medicine Department, Tumbi Regional Referral Hospital, Tanzania

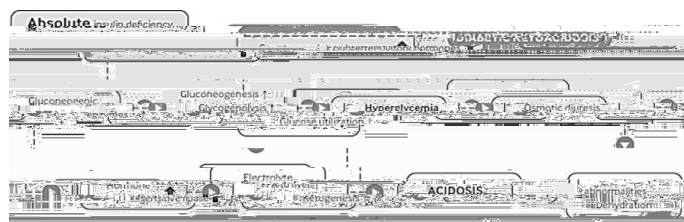



Figure 1: Pathophysiology DKA and HHS.

Received: August 20, 2021; Accepted: September 03, 2021; Published: September 10, 2021

Received: August 20, 2021; Accepted: September 03, 2021; Published: September 10, 2021

**Copyright:** © 2021 Gembe AM, et al. This is an open-access article distributed under the terms of the Creative Commons Attribution License, which permits unrestricted use, distribution, and reproduction in any medium, provided the original author and source are credited.

**Citation:** Gembe AM, Bilaro E (2021)Diabetic Keto Acidosis and Hyperosmolar Hyperglycemic State, Diagnosis and Management Challenges at Regional Referral Hospitals, A Case Series from Tumbi Regional Referral Hospital, Pwani, Tanzania. J Gastrointest Dig Syst.11:655

---

<b>Investigation</b>	<b>Results</b>
Random blood glucose	

---

**Citation:** Gembe AM, Bilaro E (2021)Diabetic Keto Acidosis and Hyperosmolar Hyperglycemic State, Diagnosis and Management Challenges at Regional Referral Hospitals, A Case Series from Tumby Regional Referral Hospital, Pwani, Tanzania. J Gastrointest Dig Syst.11:655

---

---