

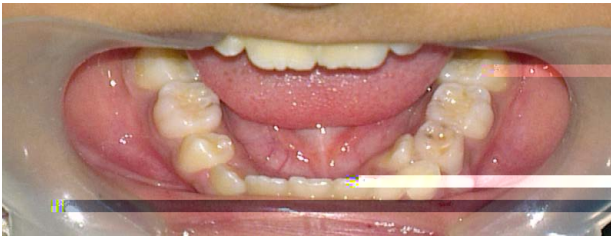
:



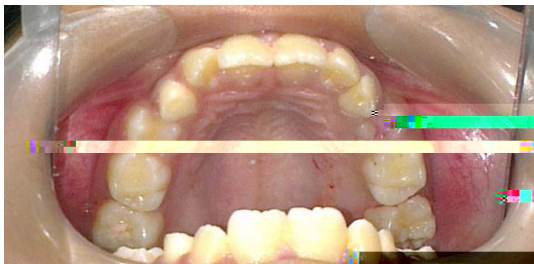P

P

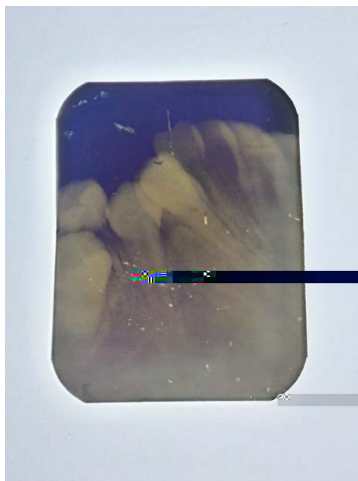
P



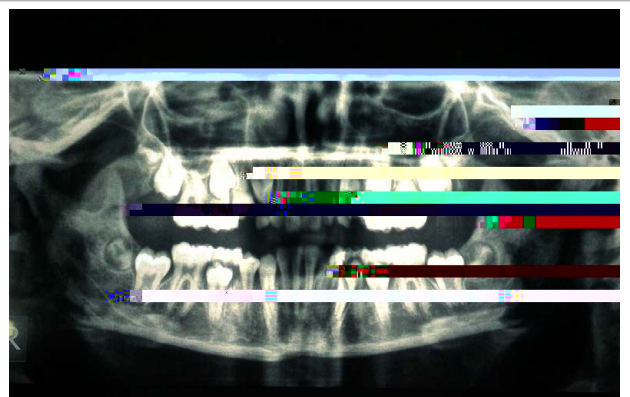
Intra Oral Picture Of Mandibular Arch Showing Transposition Of Lateral Incisor In Place Of First Premolar.



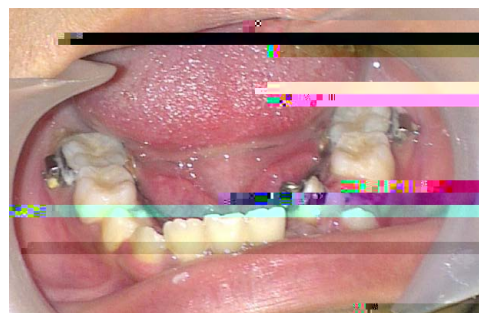Intra Oral Picture of Maxillary Arch



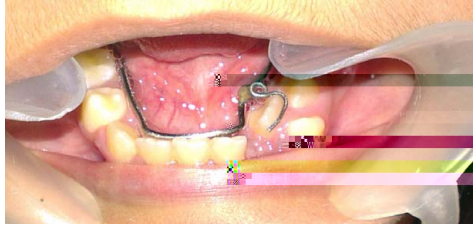
Intra Oral Periapical Radiograph Of 73 And 74 Region Shows Developing Lateral Incisor Transposition.



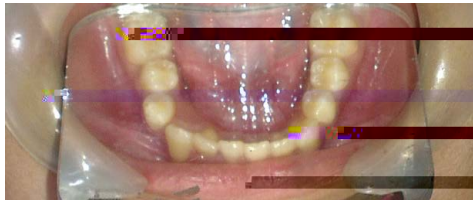Orthopantomogram Shows Developing Transposition Between Left Lateral Incisor And Left First Premolar.



Intra Oral Picture Of Mandibular Arch Shows Modified Lower Lingual Arch With Soldered Finger Spring To Correct Transposition Of Lateral Incisor.



Intra Oral Picture Of Mandibular Arch After Treatment Lateral Incisor Is In Correct Anatomical Position.



Intra Oral Picture Of Maxillary arch

1. Peck L, Peck S, Attia Y (1993) Maxillary Canine-First Premolar Transposition, Associated Dental Anomalies and Genetic Basis. *Angle Orthod* 63: 99-109.
2. Peck S, Peck L, Kataja M (1998) Mandibular Lateral Incisor-Canine Transposition, Concomitant Dental Anomalies, and Genetic Control. *Angle Orthodontist* 68: 455-466.
3. Plunkett DJ, Dysart PS, Kardos TB, Herbison GP (1998) A Study Of Transposed Canines In A Sample Of Orthodontic Patients. *British Journal of Orthodontics* 25: 203-208.
4. Shapira Y, Kuftevec MM (1989) Tooth Transpositions - A Review of The Literature And Treatment Considerations. *Angle Orthod* 59: 271-276.
5. Gholston LR, William PR (1984) Bilateral Transposition of Maxillary Canines and Lateral Incisors: A Rare Condition. *Journal of Dentistry for Children* 51: 58-63.
6. Laptok T, Silling G (1983) Canine Transposition - Approaches To Treatment. *Journal of the American Dental Association* 107: 746-748.
7. Dayal PK, Shodhan KH, Dave CJ (1983) Transposition of Canine with Traumatic Etiology. *Journal of the Indian Dental Association* 55: 283-285.
8. Canoglu E, Kocadereli I, Turgut MD (2009) Alignment of Transposed Mandibular Lateral Incisor and Canine Using Removable Appliances. *Aust Dent J* 54: 266-70.
9. Shapira Y, Kuftevec MM (2001) Maxillary Tooth Transpositions: Characteristic Features and Accompanying Dental Anomalies. *American Journal of Orthodontics And Dentofacial Orthopedics* 119: 127-134.
10. Maia FA (2000) Orthodontic Correction of A Transposed Maxillary Canine and Lateral Incisor. *Angle Orthod* 70: 339-348.