

Improved Fetal Heart Rate Study Using Update Actocardiogram

Kazuo Maeda, Department of Obstetrics and Gynecology, Tottori University Medical School, Yonago, Japan, Tel: 81-859-22-6856; E-mail:

June 20, 2016;

July 13, 2016;

July 21, 2016

© 2016 Maeda K. This is an open-access article distributed under the terms of the Creative Commons Attribution License, which permits unrestricted use, distribution and reproduction in any medium, provided the original author and source are credited.

To precisely diagnose Fetal Heart Rate (FHR) with actocardiogram (ACG), which is the simultaneous record of FHR and movement signal spikes.

Low frequency ultrasonic Doppler signal of fetal movement and high frequency Doppler of fetal heart beat were detected with single ultrasonic probe, and separated into two groups by a new electric circuit. FHR was recorded by autocorrelation heart rate meter, and fetal chest movement was changed to spikes, and their chart record was ACG.

Whole body fetal movements were recorded, because fetal body movements were conducted to fetal chest and recorded. Movement spike amplitude was parallel to fetal movement. FHR increased if fetus moved with 7 sec delay. FHR acceleration was associated with fetal movement burst, moderate movement developed moderate FHR change, and FHR variability was provoked by minor fetal movements, where fetal brain responded fetal movements then produced FHR changes by integral function of fetal midbrain. Thus, FHR changes were lost, if fetal brain was damaged by hypoxia, i.e. FHR acceleration was lost in mild hypoxia preserving variability, then the variability was lost by severe hypoxia. Problems unsolved by the CTG were solved by ACG, e.g. physiologic sinusoidal heart rate was provoked by periodic changes of fetal movements to separate pathologic one in ACG. Fetal hiccupping was not recorded by CTG but recorded by ACG. Fetal behavior was classified by ACG. Outcome of fetal bradycardia was beneficial when FHR acceleration was provoked responding to fetal movements.

Actocardiogram is a useful new device to diagnose fetal brain function.

cut-of



T e

Confirmation

confirmation

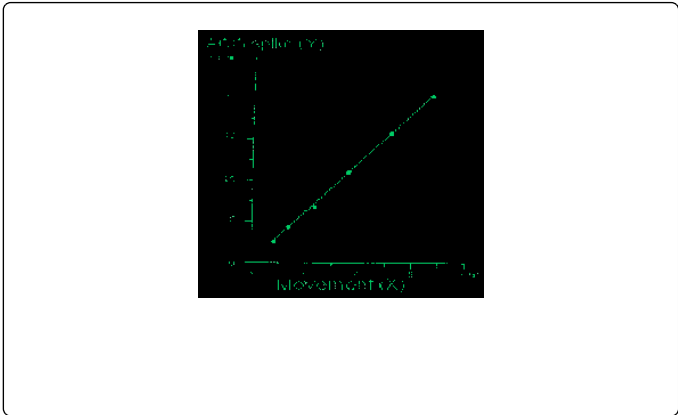
T e

Recording method of ACG

T e

fxed

T e



Fetal brain response to fetal movement

The
coefficient

FHR changes in fetal growth restriction (FGR)

Differentiation of physiologic sinusoidal FHR from
pathologic sinusoidal one

differentiate

differentiation

The differentiation