



Pyopneumothorax Caused by *Streptococcus Constellatus*: A Case Report and Literature Review

Alevrogianni F^{1*}, Psallida V² and Fildisis G³

¹

(B) (1 . 6 10 /) (1 . %) () 1, 2 . 00 12 2

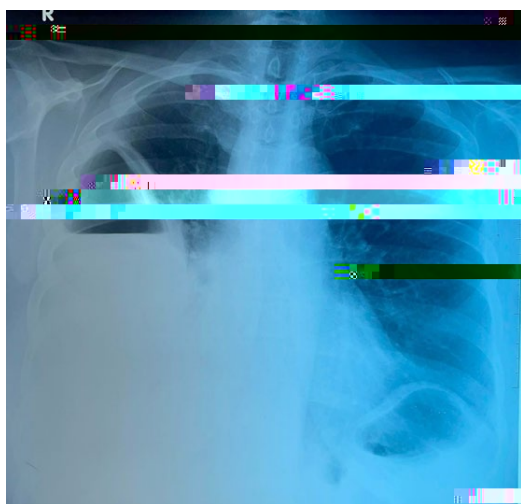


Figure 1: 12-hour follow-up chest X-ray showing pyopneumothorax.

(2 100% 2/ 2- 12). 20 / / . B (20, 10 3. %). () (). (0, %) (,) () | 3 . 2 . . B B (.) (.) + 1 . 1 .

References

1. S[á [Á UÉÁ Þá\ [[æÁ ÚÉÁ Ö^ ^) Á YÉÁ Úæ~] Á TÁ ÇGEFÍDÁ The pyogenic potential of the áá ^\^} c[[&& ^•æ) *á] [*•Á* [~] Áæ&c^!æ] •] ^&á^•KÁ^c! [•] ^&c[ç^!& [@ [ícá studyÉÁÖ] áá^ { á [[ÁQ] -^&c[FI ÍKHÉÍ ÍEHÉÍ JÉÁ
2. Þ [* ~ & @ á ÚÉÁ Yæc^!æÁ SÉÁ Sæ, æ) æ { áá VÉÁ Yæ { æ•æ\ áá SÉÁ Þæic [Á SÉÁ ^cá æÉÁ ÇGEFÍDÁ The clinical features of respiratory infections caused by the Streptococcus anginosus groupÉÁÓTÓÁÚ~ | { Á T^áÉÁGÍKFFÍKFFHÉ
3. HÉÁ Yæ { æ•æ\ áá SÉÁ Sæ, æ) æ { áá VÉÁ Yæc^!æÁ SÉÁ Ø~ \ ~ áá SÉÁ Þ [* ~ & @ á ÚÉÁ ^cá æÉÁ ÇGEFHDA Úá*) í, &æ) & ^Á [-æ) æ^! [á^•æ) áá [íæ] áæ&c^!æ] •] & [{ ~ } íc^Éæ& ~ á^áá] ^~ [[] æ. ÚS [ÚÁU] ^Á ÍKÁ^ÍHFÉHÉÁ
4. R^ } & \^! • c [í : Á ÚSÉÁ Ú [áá] • [] Á RUÉÁ T ~ í : æ~ Á ÚRÁ ÇGEFÍDÁ Invasive Streptococcus anginosus group infection-does the species predict the outcome?ÁQ) cÁRÁQ) -^&cá Ö:•FÍKÁHÍÉÍÉÁ
5. U\ æááKÓÉÁU [ACEÉÁE) á [Á YÉÁ Þá\ æ~ æ { æÁ VÉÁQ • @ áá PÉÁ^cá æÉÁ ÇGEFHDA High-resolution CT ÚáF^&•, HÍ ° ÉHÉÁ
4. p[áá] p[áá] q;HMHVSS014.60@ p[áá] DQGc5@ p[áá] @ p[áá] E0A@m 005513-8301B00of empyema due to003] TT 1 milleri us p[áá] 05.1Ap @ p[áá] @ p[áá] milleri osus7cus p[áá] 08