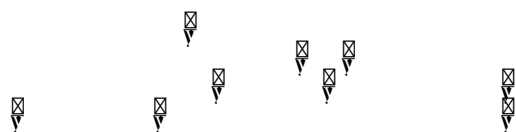


Ke d :



Pa e a d Me d













30. Mase T, Funahashi H, Koshikawa T, Imai T, Nara Y, et al. (2003) HBME-1 immunostaining in thyroid tumors especially in follicular neoplasm. *Endocr J* 50: 173-177.
31. Nasr MR, Mukhopadhyay S, Zhang S, Katzenstein AL (2006) Immunohistochemical markers in diagnosis of papillary thyroid carcinoma: utility of HBME 1 combined with CK-19 immunostaining. *Mod Pathol* 19: 1631-1637
32. Cheung CC, Ezzat S, Freeman JL, Rosen IB, Asa SL. Immunohistochemical diagnosis of papillary thyroid carcinoma. *Mod Pathol* 14: 338-342.
33. Song Q, Wang D, Lou Y, Li C, Fang C, et al. (2011) Diagnostic significance of CK19, TG, Ki67 and galectin-3 expression for papillary thyroid carcinoma in the northeastern region of China. *Diagn Pathol* 6: 126.
34. Chung SY, Park ES, Park SY, Song JY, Ryu HS (2014) CXC motif ligand 12 as a novel diagnostic marker for papillary thyroid carcinoma. *Head Neck* 36: 1005-1012.
35. Wu G, Wang J, Zhou Z, Li T, Tang F (2013) Combined staining for immunohistochemical markers in the diagnosis of papillary thyroid carcinoma: improvement in the sensitivity or specificity? *J Int Med Res* 41: 975-983.
36. Zhu X, Sun T, Lu H, Zhou X, Lu Y, et al. (2010) Diagnostic significance of CK19, RET, galectin-3 and HBME-1 expression for papillary thyroid carcinoma. *J Clin Pathol* 63: 786-789.
37. Sahoo S, Hoda SA, Rosai J, DeLellis RA (2001) Cytokeratin 19 immunoreactivity in the diagnosis of papillary thyroid carcinoma. *Am J Clin Pathol* 116: 696-702.
38. Guyotant S, Michalak S, Valo I, Saint-André JP (immun3) Diagnosis of DeLellis g DeLellis