

The Metamorphosed Girdle-Carcinoma Prostate

Anubha Bajaj*

Consultant Incharge of a Diagnostic Histopathology/ Cytopathology Laboratory, United kingdom

Introduction

Carcinoma prostate is a frequently discerned malignancy of prostate gland emerging from prostatic secretory epithelium. Tumefaction is devoid of specific or sensitive clinical and radiological features which may assist appropriate disease discernment. Neoplasm is frequently detected by non-targeted fine or core needle tissue samples obtained secondary to evaluation of elevated serum prostate specific antigen (PSA) levels [1, 2]. Additionally designated as prostate cancer or prostatic adenocarcinoma, carcinoma prostate exhibits distinctive subtypes as acinar adenocarcinoma, ductal adenocarcinoma, atrophic adenocarcinoma, pseudo-hyperplastic adenocarcinoma, microcystic adenocarcinoma, foamy gland adenocarcinoma, mucinous adenocarcinoma, signet ring variant of adenocarcinoma, pleomorphic giant cell adenocarcinoma or sarcomatoid adenocarcinoma [1, 2].

Majority of carcinoma prostate are multifocal and predominantly (~80%) confined to posterior or posterolateral peripheral zone. Few

***Corresponding author:** Anubha Bajaj, Consultant Incharge of a Diagnostic Histopathology/ Cytopathology Laboratory, United kingdom, E-mail: anubha.bajaj@gmail.com

Received: 14-Sep-2022, Manuscript No: JCD-22-76120, **Editor assigned:** 16-Sep-2022, PreQC No: JCD-22-76120(PQ), **Reviewed:** 21-Sep-2022, QC No: JCD-22-76120, **Revised:** 24-Sep-2022, Manuscript No: JCD-22-76120(R), **Published:** 29-Sep-2022, DOI: 10.4172/2476-2253.1000160

Citation: Bajaj A (2022) The Metamorphosed Girdle-Carcinoma Prostate. J Cancer Diagn 6: 160.

Copyright: © 2022 Bajaj A. This is an open-access article distributed under the terms of the Creative Commons Attribution License, which permits unrestricted use, distribution, and reproduction in any medium, provided the original author and source are credited.

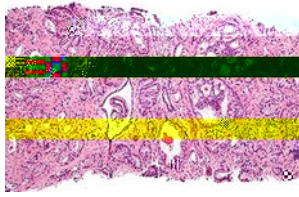


Figure 1: Carcinoma prostate depicting neoplastic glands layered by transformed columnar epithelium admixed with glands imbued with intraluminal eosinophilic aggregates and circumscribing fibrotic stroma [3].

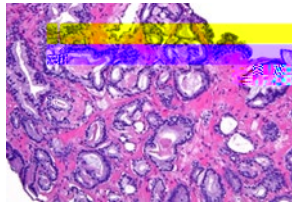


Figure 2: Carcinoma prostate delineating glands lined with neoplastic and desquamated epithelium surrounded by a dense, fibrotic stroma invaded by neoplastic glands [4].

TNM classification of carcinoma prostate is designated as **Primary tumour.**

- T1: Tumour discerned upon TURP, fine or core needle biopsy.
- T2: Tumour confined to organ and categorized as ~T2a: Tumour discerned with Digital Rectal Examination (DRE) or trans-rectal ultrasound and appears unilateral, ~T2b: Tumour discerned with Digital Rectal Examination (DRE) or trans-rectal ultrasound and extends to contralateral segment, ~T2c: Tumour discerned with Digital Rectal Examination (DRE) or trans-rectal ultrasound and appears bilateral
- T3 designated as ~T3a: Tumour with focal or multifocal extra-prostatic extension or microscopic invasion of dense musculature of urinary bladder neck with absence of adjacent non-neoplastic glands, ~T3b: Tumour invasion into musculature of seminal vesicle.
- T4: Tumour invasion into external urethral sphincter, rectum, bladder, levator muscles or pelvic wall.

Regional Lymph Nodes

- NX: Regional lymph nodes cannot be assessed
- N0: Regional lymph node metastasis absent
- N1: Regional lymph node metastasis present

Regional lymph nodes are exemplified by peri-prostatic, pelvic, hypogastric, obturator, internal iliac, external iliac or sacral lymph nodes.

Distant Metastasis

- M0: Distant metastasis absent.
- M1 is designated as ~M1a: Distant metastasis into non-regional lymph nodes as aortic, common iliac, superficial inguinal, deep inguinal or retroperitoneal lymph nodes, ~M1b: Distant metastasis into bone, ~M1c: Distant metastasis into diverse viscera [2, 5].

Gleason grading of carcinoma prostate is contingent to tumour architecture and represents a morphological continuum of well-formed glandular pattern to complex glandular proliferation or lack of

glandular differentiation. Gleason grades are designated as:

- Grade X: Gleason score cannot be determined.
- Grade 1 (Gleason score 6): Individual, discrete, well circumscribed glands and serum PSA <10 ng/ml or between 10 ng/ml and 20 ng/ml.
- Grade 2 (Gleason score 3+4=7): Predominant well circumscribed glands with a minimal component of inadequately defined, fused or cribriform glands and serum PSA <20ng/ml.
- Grade 3 (Gleason score 4+3=7 or 8): Predominant inadequately circumscribed, fused or cribriform glands with miniscule component of well circumscribed glands and serum PSA <20ng/ml.
- Grade 4 (Gleason score 8): Singularly composed of inadequately circumscribed, fused or cribriform glands or predominantly well circumscribed glands with minor component devoid of glands or a tumefaction predominantly devoid of glands with miniature component of well circumscribed glands and serum PSA <20 ng/ml.
- Grade 5 (Gleason score 9 or 10): Absence of glandular formation or glands associated with necrosis along with or devoid of inadequately circumscribed, fused or cribriform glands and an elevated serum PSA level [2, 5].

Clinically, grade 1 denominates a morphological 'low grade', grade 2 exemplifies an 'intermediate grade' and grade 3 or elevated grade enunciates 'high grade' neoplasms [2, 5].

Staging of carcinoma prostate is denominated as:

- Stage I: Tumour is preliminary, non-palpable, and gradually progressive and incriminates unilateral aspect of prostate. Serum PSA levels are minimal. Tumour cells simulate uninvolved prostatic epithelium.
- Stage II: Tumour confined to prostate. Serum PSA levels are minimal to moderate. Progression and dissemination of miniature tumefaction is exemplified.
- Stage IIA: Tumour is non-palpable and unilateral. Serum PSA levels are moderately elevated. Neoplastic cells are well differentiated. Enlarged neoplasms composed of well differentiated prostatic epithelial cells confined to prostate are categorized as stage IIA neoplasms.
- Stage IIB: Tumour is confined to prostate and appears palpable upon direct rectal examination (DRE). Serum PSA levels are moderately elevated. Tumour cells are moderately differentiated.
- Stage IIC: Tumefaction is confined to prostate and appears palpable upon DRE. Serum PSA levels are moderately elevated. Neoplastic cells are moderately or poorly differentiated.
- Stage III: Serum PSA levels are significantly elevated. Tumour is high grade and progressive. The stage is constituted of locally advanced prostatic carcinoma with significant tumour progression and metastasis.
- Stage IIIA: Tumefaction extends beyond extrinsic layer of prostate into circumscribing soft tissues or seminal vesicles. Serum PSA levels are significantly elevated.
- Stage IIIB: Tumefaction extends beyond prostate gland with extension into adjacent viscera as urinary bladder or rectum.
- Stage IIIC: Tumour cells appear poorly differentiated.

- Stage IV: Tumefaction extends beyond prostate ~ stage IVA: Tumefaction depicts regional lymph node metastasis, ~stage IVB: Tumefaction disseminates into distant lymph nodes, diverse viscera or bones [2, 5].

Recurrent carcinoma prostate is denominated by neoplastic reappearance following therapy. Tumour may re-emerge within prostatic zone or diverse areas. Extent of tthin
