

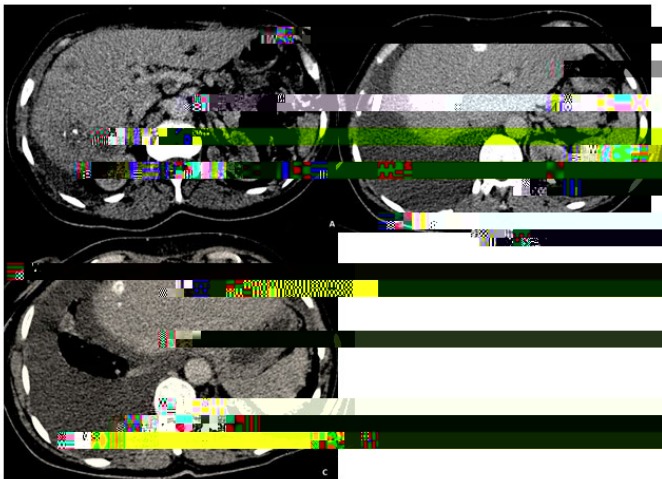
Detecting Calcified Liver Metastasis in Breast Cancer

Radiology Department of national institute of oncology of Rabat, Morocco

Clinical Image

Calcified liver metastases in breast cancer are rare. We report a case of calcified liver metastases detected on CT scan of a 54-year-old female patient with a history of breast cancer.

On a routine CT scan, calcified liver metastases were detected. In this case, CT scan is a useful tool for the detection of calcified liver metastases (Figure 1), which can be detected on CT scan. Detection of calcified liver metastases is important for the diagnosis of breast cancer (Figure 1).



Treatment of calcified liver metastases in breast cancer is challenging. The mainstay of treatment is systemic therapy, including chemotherapy, endocrine therapy, and targeted therapy. In this case, the patient was treated with tamoxifen and endocrine therapy.

In conclusion, calcified liver metastases in breast cancer are rare. CT scan is a useful tool for the detection of calcified liver metastases. Detection of calcified liver metastases is important for the diagnosis of breast cancer.

1. Wan CK, Chen LP, Chen HY, Yang SS, Hu JT (2020) Triple-negative breast cancer with calcified metastases of hepatic, portal vein and inferior vena cava: Report of a case and review of the literature. *J Formos Med Assoc* 119: 1431-1434.
2. Shonfeld EM, Guarino AV, Bessolo RJ (1973) Calcified hepatic metastases from carcinoma of the breast. *Radiology* 106: 303-304.

Yassine Zerhari, Radiology Department of national institute of oncology of Rabat, Morocco, E-mail: Yassine.zerhari1@gmail.com

04-Apr-2023, Manuscript No. roa-23-94423; 06-Apr-2023, PreQC No. roa-23-94423 (PQ); 20-Apr-2023, QC No. roa-23-94423; 22-Apr-2023, Manuscript No. roa-23-94423 (R); 29-Apr-2023, DOI: 10.4172/2167-7964.1000437

Zerhari Y, Bakkari A, Alloui S, Jerguigue H, Omor Y, et al. (2023) Detecting Calcified Liver Metastasis in Breast Cancer. *OMICS J Radiol* 12: 437.

© 2023 Zerhari Y, et al. This is an open-access article distributed under the terms of the Creative Commons Attribution License, which permits unrestricted use, distribution, and reproduction in any medium, provided the original author and source are credited.